

Pedunculated Parietal Peritoneal Leiomyoma

Dr. Surya Prakash¹, Dr.K.V.Rama Rao², Dr.P.Raja Babu³,

¹ Surya Prakash, Junior Resident, General Surgery, Dr.Pinnamaneni Siddhartha Institute Of Medical Sciences & Research Foundation, Chinaoutapalli, Krishna Dist, Andhra Pradesh, India.

² Dr.K.V.Rama Rao, M.S., General Surgery, Professor, Dr.Pinnamaneni Siddhartha Institute Of Medical Sciences & Research Foundation, Chinaoutapalli, Krishna Dist, Andhra Pradesh, India.

³ Dr.P.Raja Babu. M.S., General Surgery, Professor, Dr.Pinnamaneni Siddhartha Institute Of Medical Sciences & Research Foundation, Chinaoutapalli, Krishna Dist, Andhra Pradesh, India.

Abstract: We present a rare case of 40 yrs woman with mass in the abdomen of 5 months duration. Investigations revealed a large abdomino-pelvic intraperitoneal lesion for which laparotomy was done and a pedunculated intraperitoneal mass was found attached to the parietal peritoneum of the lower anterior abdominal wall.

It was excised and sent for histo pathological examination, which was suggestive of Myxoid Leiomyoma of parietal peritoneum.

Keywords: Pedunculated Intraperitoneal leiomyoma, Myxoid Leiomyoma of parietal peritoneum

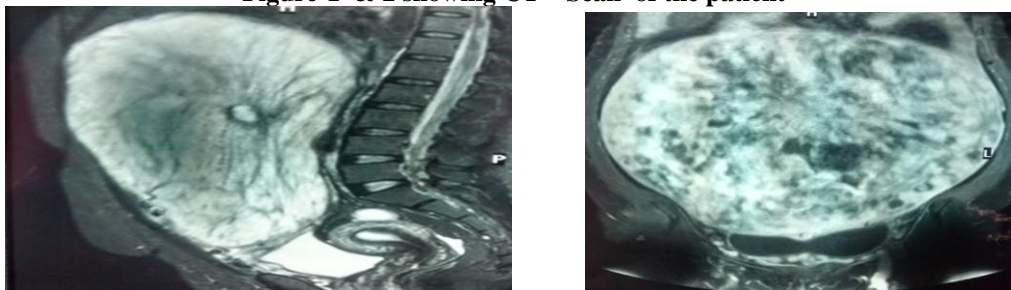
I. Introduction

Leiomyomas are the commonest benign tumours of the reproductive tract and are found in 20% of women of reproductive age^[1] Extrauterine leiomyomas are uncommon, generally benign and occasionally cause diagnostic dilemmas as they can mimic malignancy. Parietal peritoneal Leiomyoma of Anterior abdominal wall is rare and there are very few reported cases of primary Parietal peritoneal leiomyoma without previous uterine surgeries or concomitant presence of uterine fibroids^[2]. This is a case report of a Solitary Peritoneal Leiomyoma arising from the abdominal wall that presented as an adnexal mass in a Perimenopausal woman.

Observations

A woman aged 40 yrs old female patient presented with abdominal swelling since 5 months, initially below umbilicus, gradually increased to the whole of the abdomen, associated with loss of body weight of 10kgs. No history of pain, vomiting, altered bowel habits or urinary symptoms. She has 3 children with last child birth 20 years back. She underwent tubectomy 19yrs back. Her menstrual cycles were normal with LMP on 20 days prior to presentation. General examination was unremarkable. Abdominal examination revealed an oval mass 29x30cms occupying all regions of abdomen, with upper border 10 cm below xiphisternum. No local rise of temperature, non tender, firm in consistency, mobile in horizontal plane and with restricted mobility in vertical plane. All borders well made out except lower border. Dull on percussion, no bruit on Auscultation. External genitalia are normal, internal examination showed normal vagina and cervix. Non tender firm mass felt through Right fornix. Uterus was normal with other free Fornices. Per rectal examination was normal. A clinical diagnosis of Right Ovarian Mass was done.

Figure-1 & 2 showing CT – Scan of the patient



Abdominal ultrasonography revealed a Large Heterogeneous Mass of size 23x19cm occupying Abdomen & Pelvis, extending in Abdomen Up to Epigastric Region. Right Ovary Not visualised. MRI of Pelvis and Abdomen revealed a Large enhancing Abdomino – Pelvic Intraperitoneal lesion (28.6x27.5x11.5 cm) Possibly Mesenchymal Tumour or GIST. Ovaries and Uterus – Normal[Figure 1,2].CA-125 levels were 26U/ml(within normal limits).

Figure-3 & 4

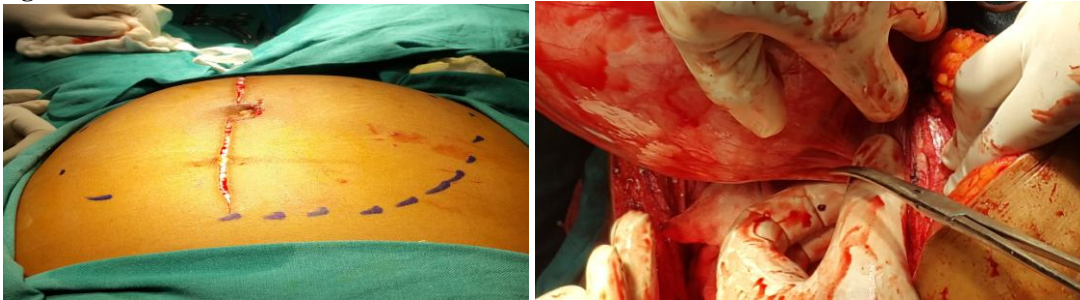

Fig 5 & 6

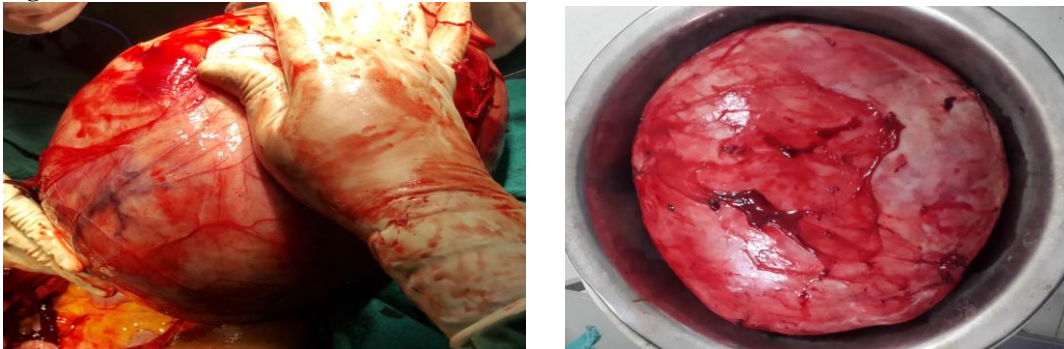
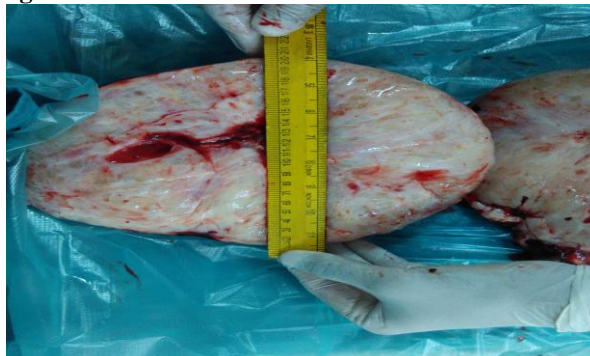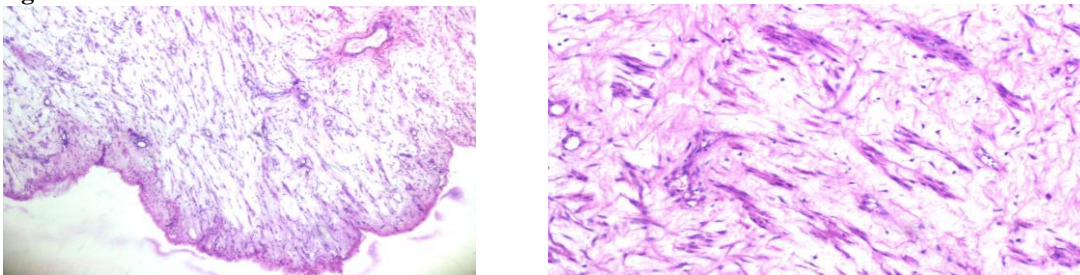


Fig 7



Exploratory laparotomy was performed with midline incision, which revealed a Pedunculated intraperitoneal mass with smooth surface attached to parietal peritoneum of lower anterior abdominal wall at the level of pubic symphysis towards right side. The mass was completely excised. It was firm, measuring 25x19x16 cm weighing 6kgs. Uterus and ovaries were normal. Primary anatomical closure was done [Figure 4,5,6,7]. The histopathological examination was suggestive of Myxoid Leiomyoma showing bundles of smooth muscle cells with cigar shaped nucleus with Myxoid change and foci of haemorrhagic and Necrotic foci [Figure 8,9]. Her postoperative recovery was uneventful. Immunohistochemistry showed Tumor cells are strongly positive for both SMA and DESMIN, C-KIT Negative.

Fig 8 & 9



II. Discussion

Leiomyomata are benign mesenchymal tumours originating from smooth muscles. Uterine leiomyoma is the most common benign gynaecological tumour affecting as many as 25% of women in the reproductive age group,^[3] and is present in about 80% of all hysterectomy specimens.^[4] A leiomyoma arising from the parietal layer of peritoneum is so rare that even with modern advances in imaging techniques, its imaging features have rarely been described for preoperative characterization and diagnosis. Among the tumours that are completely resected, however, the rates of recurrence and metastasis are very rare.^[9] It is thought to result from seedling following surgical resection of uterine leiomyoma^[5],^{[6],[7]}, which are more likely following laparoscopic procedures than laparotomy.^{[5],[8]} Our patient gives no history of undergoing any kind of surgery for uterine leiomyomata in the past.

III. Conclusion

Solitary myxoid leiomyoma is a rare smooth muscle tumour that may arise in the peritoneum in the absence of previous uterine surgeries or concomitant presence of uterine fibroids.

Bibliography

- [1]. Kjerulff KH, Langenberg P, Seidman JD, Stolley PD, Guzinsky GM. Uterine leiomyomas. Racial differences in severity, symptoms and age at diagnosis. *J Reprod Med.*1996;41(7):483-90.
- [2]. Igberase OG, Mabiaku OT, Ebeigbe PN, Abedi HO. Solitary anterior abdominal wall leiomyoma in a 31-year-old multipara woman: A case report. *Cases J.* 2009;2(1):113.
- [3]. Buttram VC Jr, Reiter RC. Uterine leiomyomata: Aetiology, symptomatology, and management. *Fertil Steril* 1981;36:433-45.
- [4]. Cramer SF, Patel A. The frequency of uterine leiomyomas. *Am J Clin Pathol* 1990;94:435-8.
- [5]. Moon HS, Koo JS, Park SH, Park GS, Choi JG, Kim SG. Parasitic leiomyoma in abdominal wall after laparoscopic leiomyomectomy. *Fertil Steril* 2008;90:1201-1202.
- [6]. One M, Tanaka K, Ikezawa N, et al. Fibroma of the omentum resembling an ovarian tumour in the pelvis. *Keio J Med* 2009;58: 234-236.
- [7]. Lalor PF, Uribe A, Daun GS. Denovo growth of a large preperitoneal leiomyomata of the anterior abdominal wall. *Gynaecol Oncol* 2005;97(2):719-721
- [8]. Ostrzenski A. Uterine leiomyoma particle growing in abdominal wall incision after laparoscopic retrieval. *Obstet Gynaecol* 1997; 89(2): 853-4
- [9]. Billings SD, Folpe AL, Weiss SW. Do leiomyomas of deep soft tissue exist? An analysis of highly differentiated smooth muscle tumours of deep soft tissue supporting two distinct subtypes. *Am J Surg Pathol* 2001;25:1134-42.